

The ASE Example Case Report 2010

The Requirements for Case Presentation in The Angle Society of Europe are specified in the Appendix I to the Bylaws.

This example case report exemplifies how these requirements can be met. It should be stressed however that it is only an example and that individualised presentations are accepted as long as the outline in the Requirements for Case Presentation are followed.

Some practical aspects need to be explained. The superimpositions in the example case were made according to “The structural Method” by Professor Arne Björk. This procedure is mandatory. (See Guide to superimposition of profile radiographs by “The structural Method”).

For evaluation of the general facial changes the profile radiographs have been superimposed on the stable structures in the anterior cranial base.

For evaluation of the changes in the maxilla and in the mandible the profile radiographs have been superimposed on the stable structures in the maxilla and in the mandible respectively.

The treatment of the patient and the preparation of the report has been carried out by Dr. Per Rank.

Copyright © 2010 The Angle Society of Europe.

All Rights Reserved. Any unauthorized public performance or broadcasting of this record is prohibited.

RESUME OF CASE J.L.

Born : 1/4 1982

Sex : Male

Pretreatment records	:	Age 10 ⁶	Date : 17/9 1992
Classification	:	Angle Class II, division 1	
Teeth missing before treatment	:	None	
Treatment plan	:	I) Nonextraction growth modification II) Level and alignment of the arches	
Appliance	:	Expansion plate , lower lip bumper Activator-headgear Edgewise appliance	
Treatment started	:	Age 10 ⁷	Date : 22/10 1992
Treatment ended	:	Age 12 ⁷	Date : 18/10 1994
Active treatment time	:	2 Years	
Posttreatment records	:	Age 13 ⁴	Date : 8/8 1995
Retainers	:	3-3 retainer, Mini-Activator	
Retention ended	:	Age 14 ⁷	Date : 5/11 1996
Retention time	:	2 years	
Postretention records	:	Age 17 ⁹	Date : 13/1 2000
Time out of retention	:	3 years and 2 months	

HISTORY AND GENERAL CLINICAL PICTURE.

A. Anamnesis :

A healthy boy aged 10 years and 6 months was referred by his general dentist for orthodontic treatment. There was no history of headache, thumb sucking or enlarged adenoids. There had been an injury to the upper front teeth at the age of seven.

B. Examination of the head and face :

The boy looked healthy and with a normal facial appearance apart from the protruding upper incisors and incompetent lips.

C. Functional examination :

Incompetent lips with the lower lip functioning behind the upper incisors during swallowing. When the patient closed his lips, a marked strain in the mentalis muscle was observed.

No muscle pain , TMJ problems or CR-CO discrepancy was observed. The opening movement was symmetrical and within normal limits.

D. Intraoral examination :

The gingiva looked healthy and the oral hygiene was reasonably good. An impression of the lower incisors in the palatal mucosa behind the upper centrals was evident. The enamel was well mineralized apart from a white spot at the incisal edge of the upper right central incisor. A brown discoloration of the lower left first molar was evident but revealed no caries.

E. Dental casts :

Dental stage : DS 3 M1 : (DS 3: All permanent incisors were in occlusion, and the permanent canines and premolars were erupting; M 1: The permanent first molars were in occlusion)

Maxillary arch : Narrow upper arch with normal space conditions.

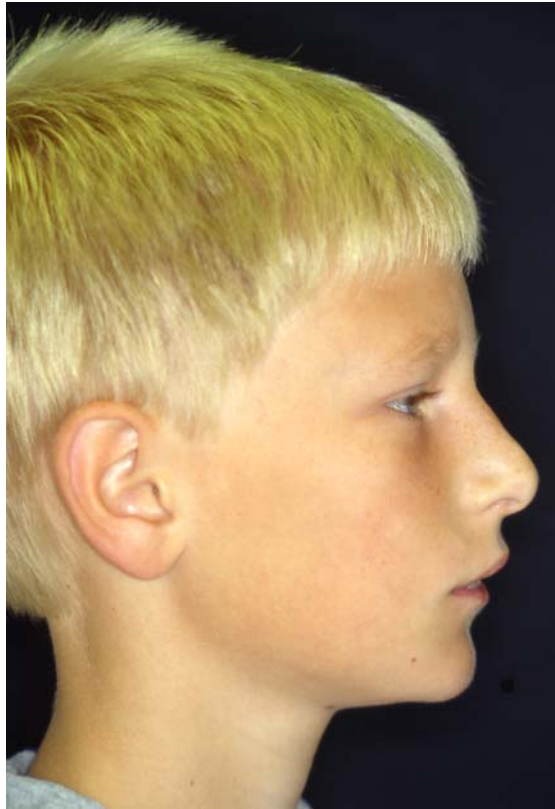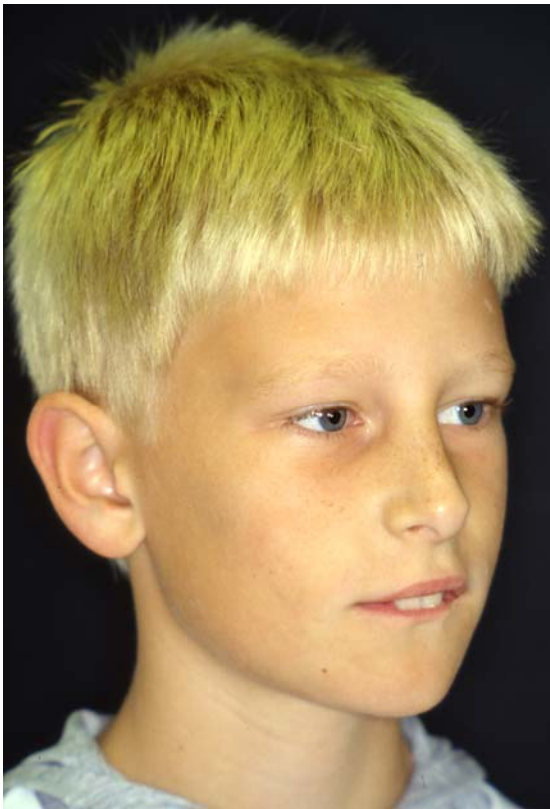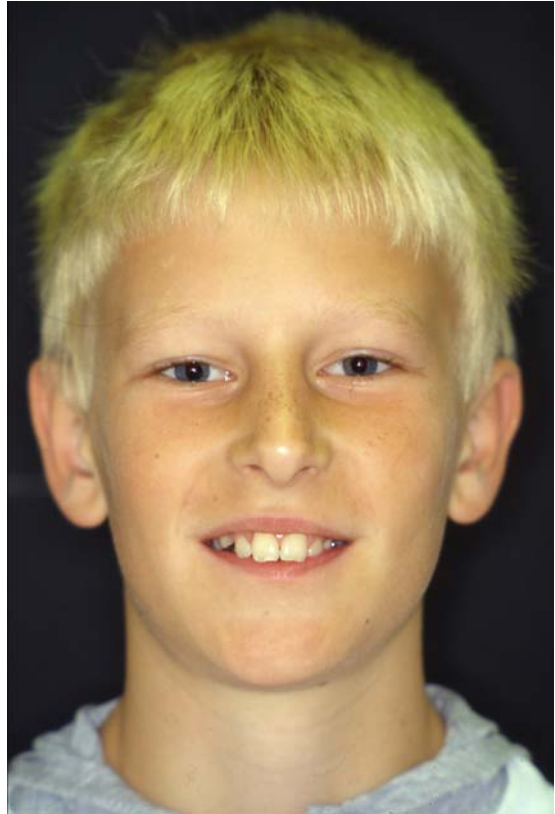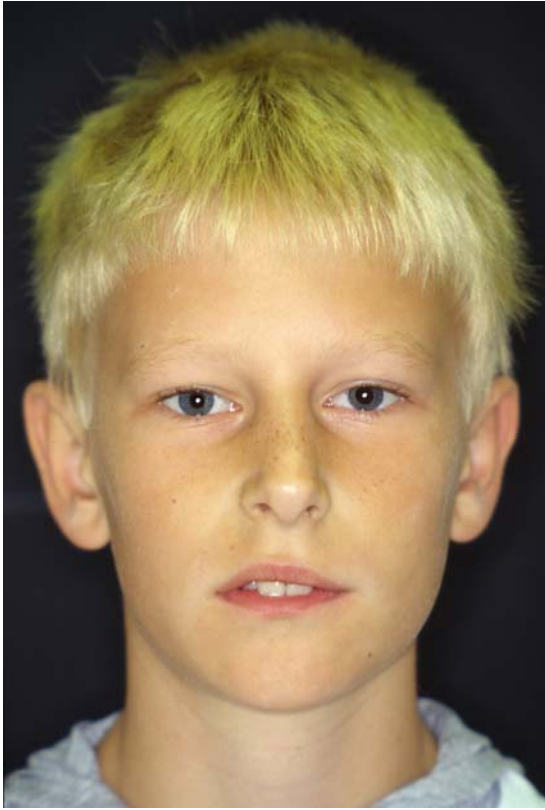Mandibular arch : Normal lower arch with normal space conditions.

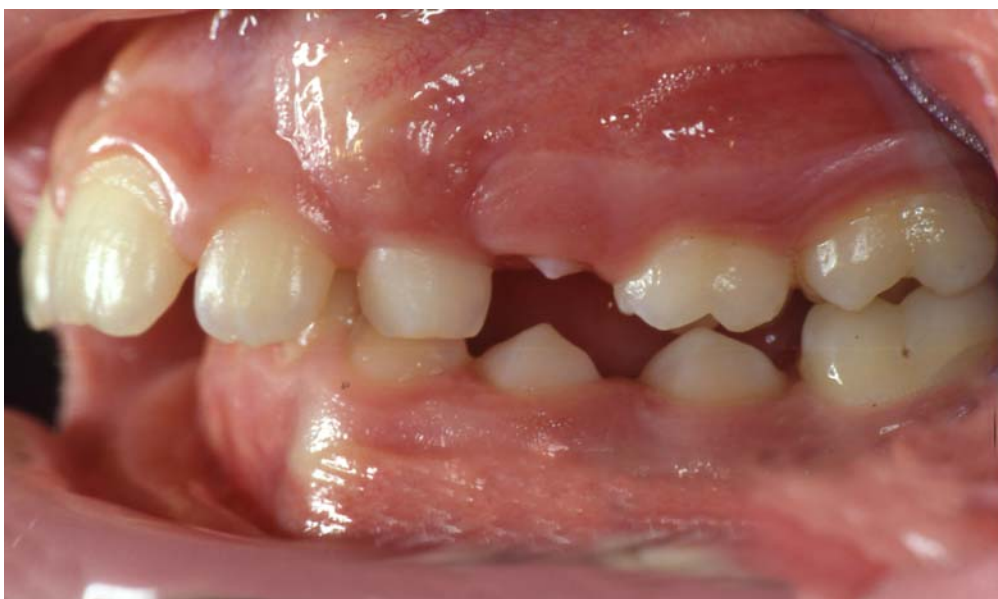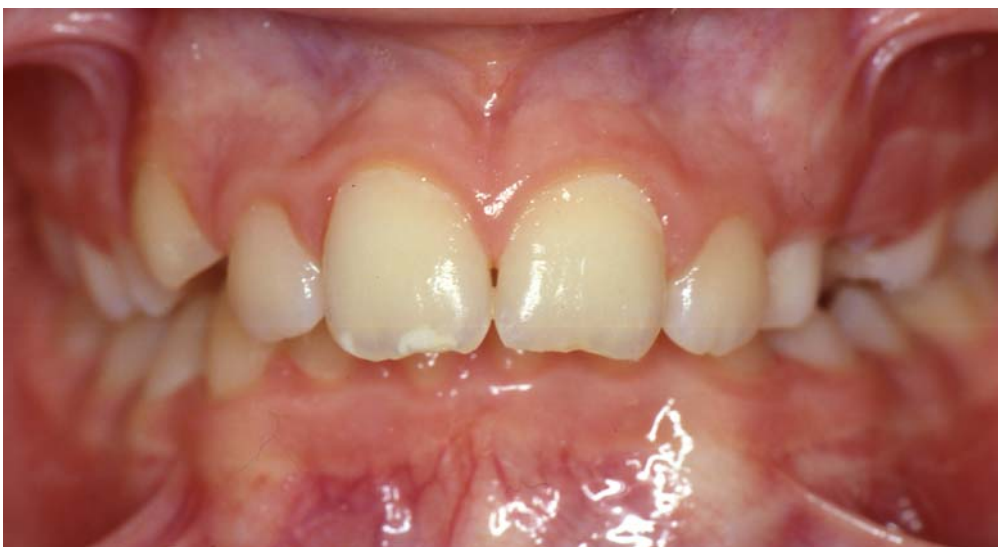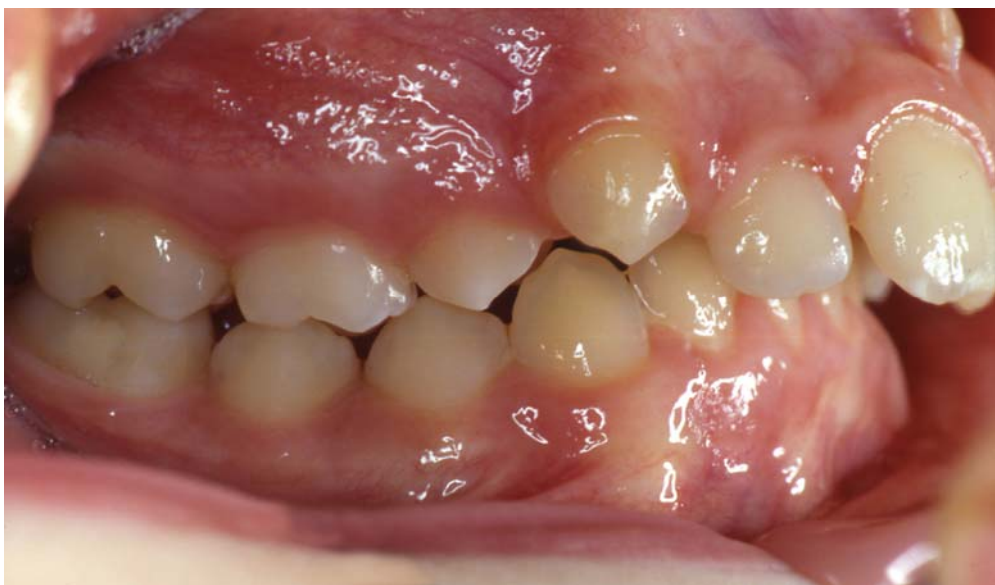Occlusion:

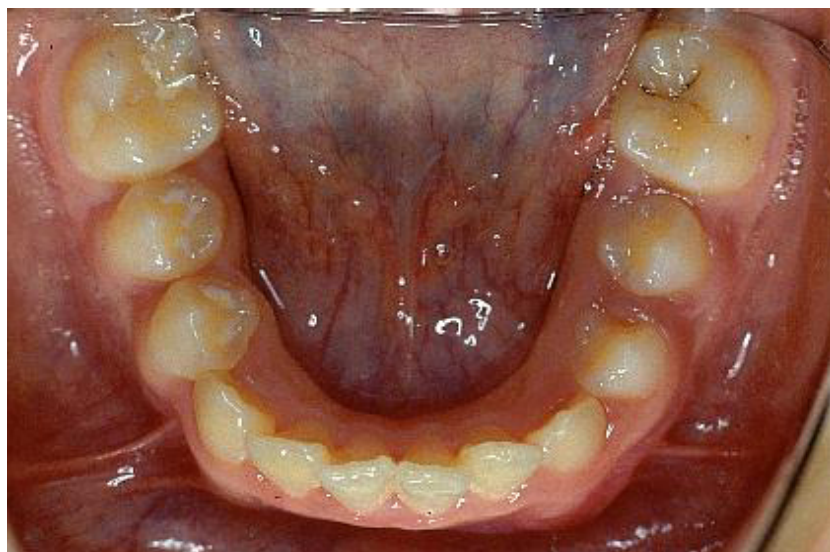
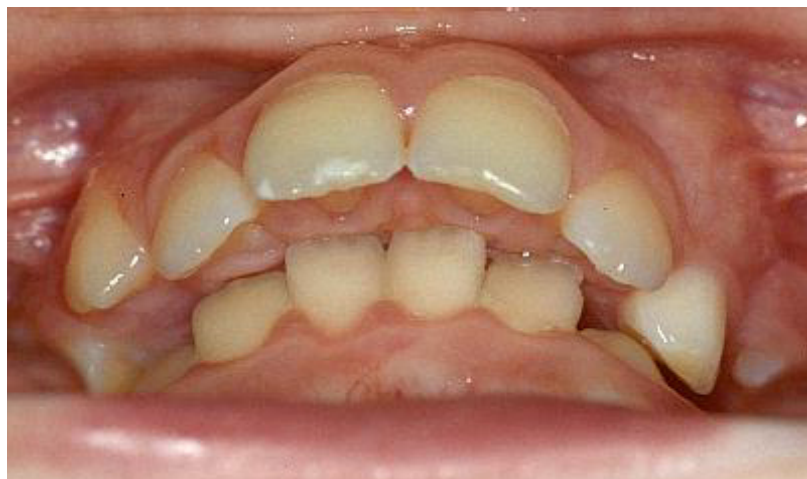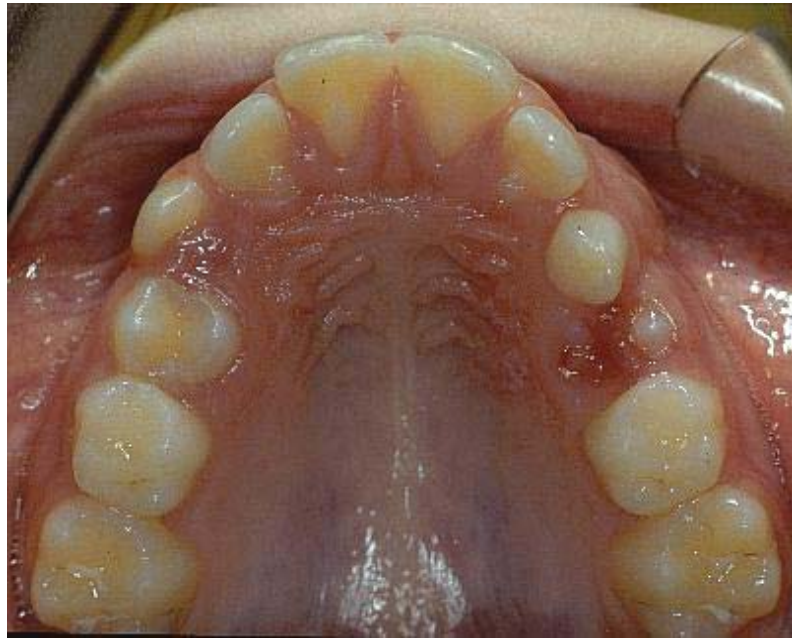Sagittal : Overjet 12 mm , a full class II molar relation on the right side, and half a class II on the left side.

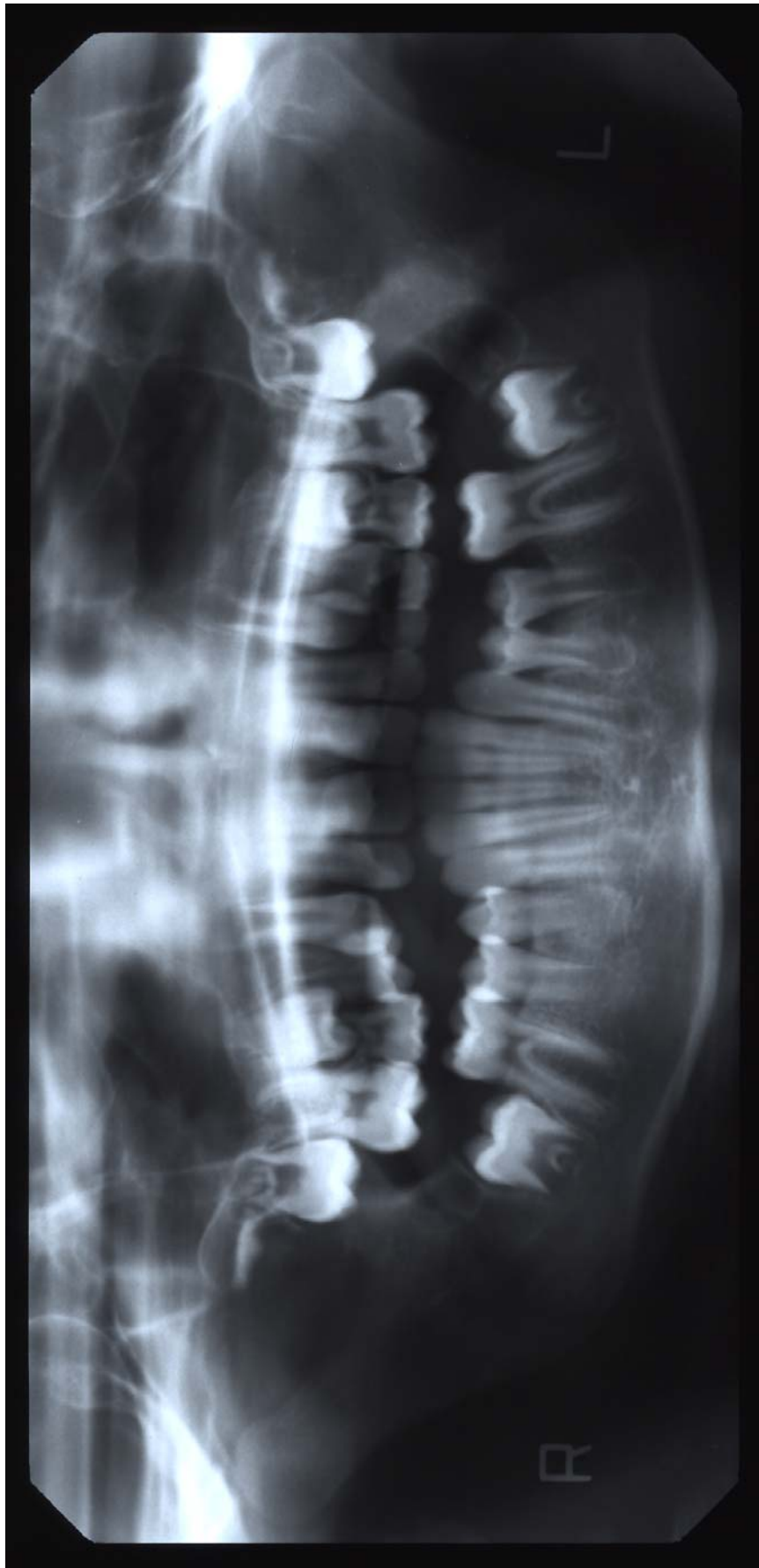Vertical : Overbite 7 mm.

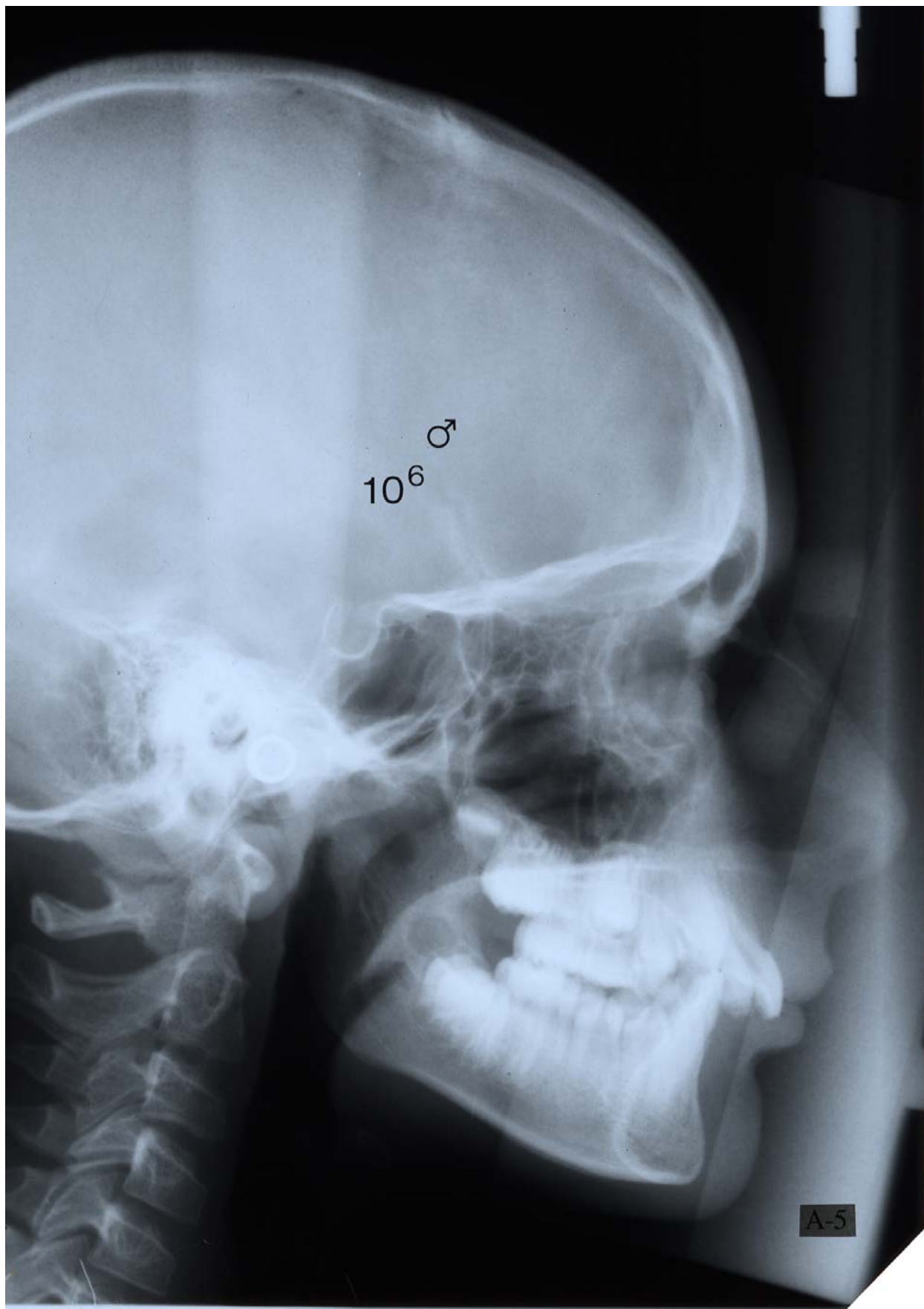
Transverse : Normal.





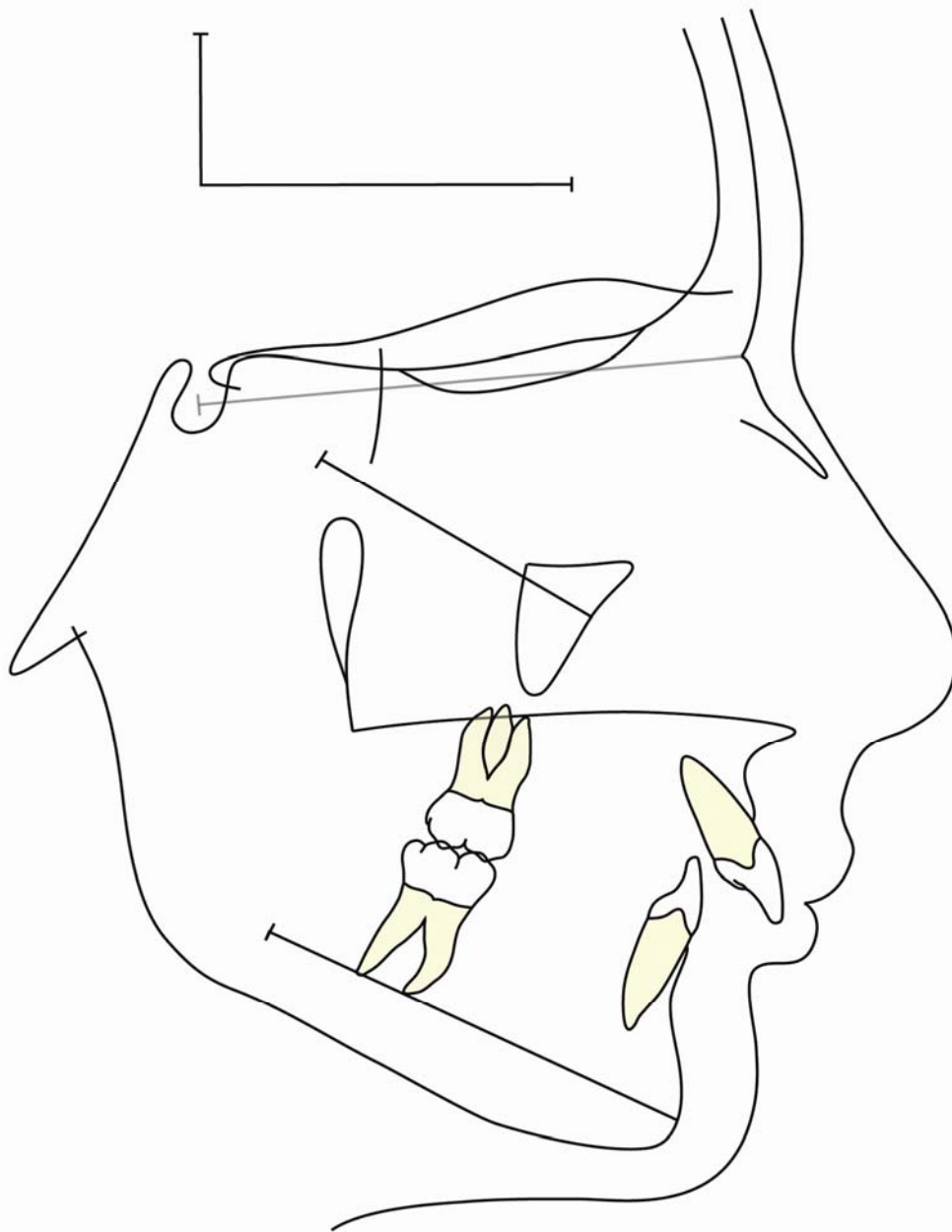






A-5

Case J.L.
Pre-Treatment 10⁶



CHEPHALOMETRIC MORPHOLOGICAL ASSESSMENT I

Sagittal Skeletal Relations

Maxillary Position
S-N-A
Mandibular Position
S-N-Pg
Sagittal Jaw Relation
A-N-Pg

Pretreatment	Mean	SD
85°	82°	3.5
80°	80°	3.5
5°	2°	2.5

Vertical Skeletal Relations

Maxillary Inclination
S-N/ANS-PNS
Mandibular Inclination
S-N/GO-Gn
Vertical Jaw Relation
ANS-PNS/Go-Gn

5°	8°	3.0
28°	33°	2.5
23°	25°	6.0

Dento-Basal Relations

Maxillary Incisor Inclination
1 - ANS-PNS
Mandibular Incisor Inclination
1 - Go-Gn
Mandibular Incisor Compensation
1 - A-Pg (mm)

118°	110°	6.0
88°	94°	7.0
-4	2	2.0

Dental Relations

Overjet (mm)

Overbite (mm)

Interincisal Angle
1/1

12	3.5	2.5
7	2	2.5
129°	132°	6.0

RADIOGRAPHIC ANALYSIS.

A. Panoramic radiograph :

The panoramic radiograph revealed presence of all permanent teeth. The roots of the incisors appeared normal and no abnormal positions of the permanent tooth germs were observed.

B. Cephalometric radiograph :

The cephalometric morphological assessment showed increased maxillary prognathism and normal mandibular prognathism, resulting in an increased sagittal jaw relationship.

Both jaws were slightly anteriorly inclined with a slightly decreased vertical jaw relationship.

The upper incisors were proclined and the lower incisors retroclined.

The extreme overjet (12 mm) was of skeletal origin, due to the increased maxillary prognathism. The upper incisors were dysplastically proclined and the lower incisors were dysplastically retroclined.

The interincisal angle was slightly decreased and the lower incisors were quite far back in the face (-4 mm to APg).

The deep overbite (7 mm) with the compression of the palatal mucosa was of skeletal origin due to the decreased vertical jaw relationship.

A. Etiology :

No clear etiology seems to explain the extreme discrepancy. The growth pattern of the mandible seems normal, so the development of the abnormal function of the lower lip may have been due to an early thumb sucking habit or it may have developed accidentally.

B. Diagnosis :

Angle Class II, division 1. Extreme overjet of both skeletal and dentoalveolar origin. Class II molar relationship. Extreme deep overbite of skeletal origin. Abnormal lower lip function, with incompetent lips.

C. Plan of Treatment :

Based on the anticipation of a favourable anterior growth pattern and the patients young age , a non extraction - growth modification - treatment protocol was decided.

The treatment plan was divided into two phases.

Phase I :

The objectives of the first treatment phase were to inhibit the forward maxillary growth and stimulate the forward growth of the mandible and procline the lower arch, to establish a normal incisal relationship and a class I molar relationship and a normal lip function.

An upper **Expansion Plate** was chosen to broaden the upper arch and a **Lower Lip Bumper** to reduce the effect of the lower lip.

After this initial preparation of the arches an **Activator-Headgear** appliance was chosen.

Phase II :

The objectives of the second treatment phase were to level and align the arches and establish a solid occlusion. An **Edgewise Appliance** was chosen

.

Retention Phase :

A **3-3 Bonded Retainer** for many years and a **Mini-Activator** at night for two years.

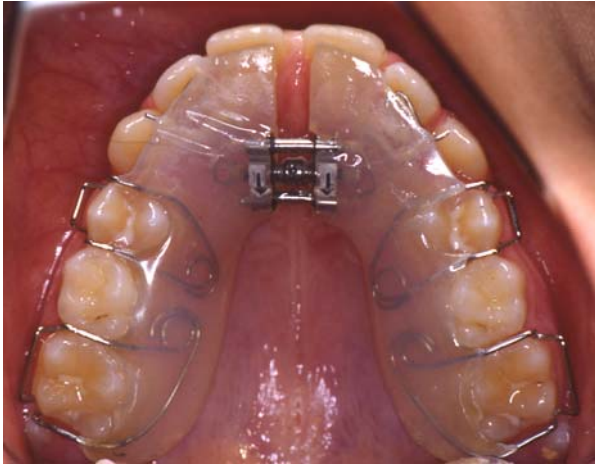
DISCUSSION OF TREATMENT PLAN

A number of different appliances could have been chosen in this particular case. A full fixed appliance with a cervical headgear and class II elastics or a Herbst-type appliance could have corrected the malocclusion, as could an activator-only appliance. The reason for choosing the activator-headgear combination was the wish for a better vertical control of the maxilla and a better torque control of the upper incisors during the class II correction.

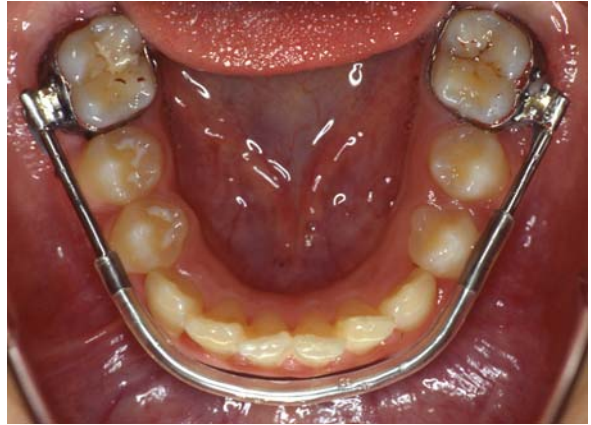In this deep bite case with a lot of growth left, a slight protrusion of both the upper and lower incisors resulting in a reduced inter incisal angle, seems to be the best way to prevent a future relapse of the deep overbite. The activator-only appliance would therefore have been the worst choice in this particular case.

Progress of case :

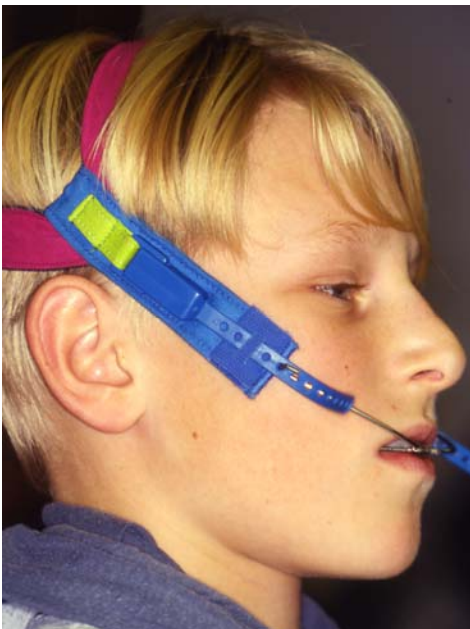17/09 1992	Pre-treatment records
20/11	Lower lip bumper
8/02 1993	Upper expansion plate
28/05	Activator-Headgear, Overjet 11 mm, Records
17/06	Control, Overjet 9 mm.
5/08	Control, Overjet 7 mm.
9/09	Control, Overjet 6 mm.
28/09	Acute appointment due to pain and infection around erupting 27. Chlorhexidin and Penicillin.
18/10	Control, Overjet 6 mm.
9/11	Control Overjet 5 mm.
16/12	Control, Overjet 4½ mm, Records
13/01 1994	Control, Overjet 4 mm.
19/04	Control, profile radiograph.
20/05	Full edgewise appliance upper and lower jaw, .012 Aust.wire.
03/06	High pull headgear and .014 Aust.wire U /L
21/07	Brackets lower second molars .016 s.s. U / L
01/09	.016 x .016 s.s, U / L, High pull headgear and class II elastics
29/09	Stripping of lower incisors, impressions.
18/10	Removal of fixed appliance, 3-3 retainer
20/10	Mini-Activator (Acti-splint)
8/08 1995	Records
5/11 1996	End of retention, records
13/01 2000	Records



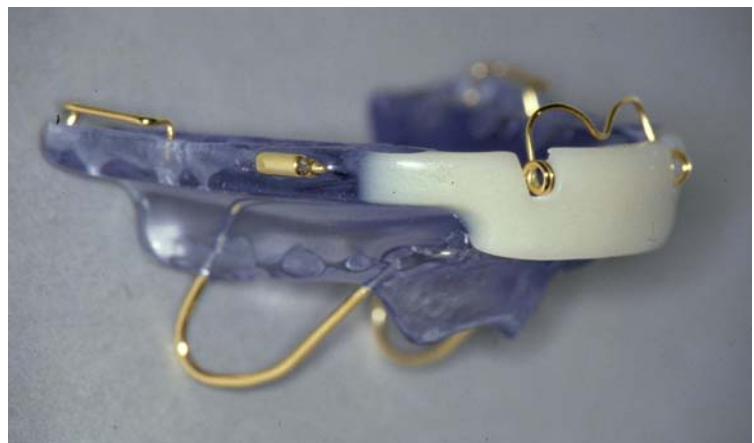Upper expansion plate



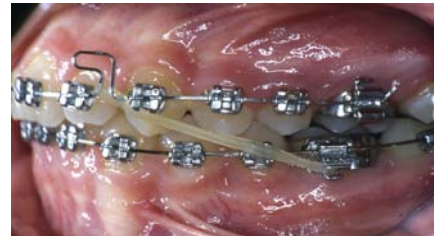
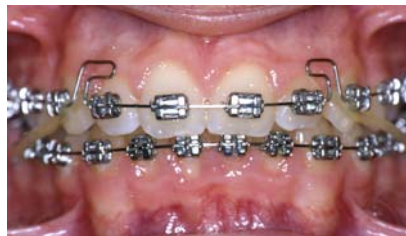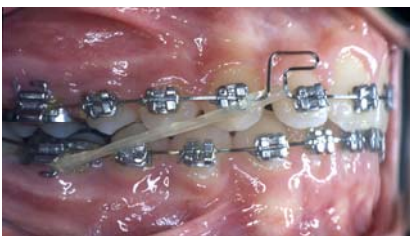Lower lip bumper



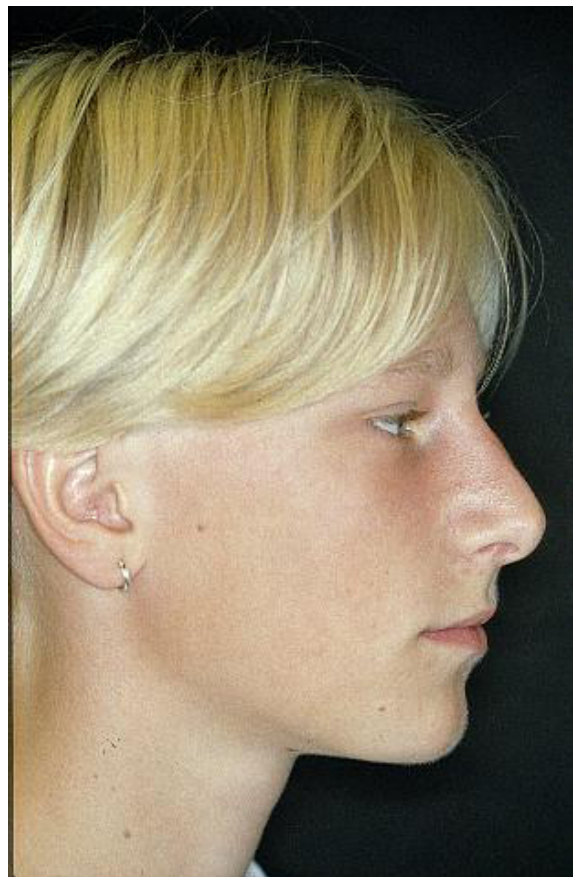
High - pull headgear



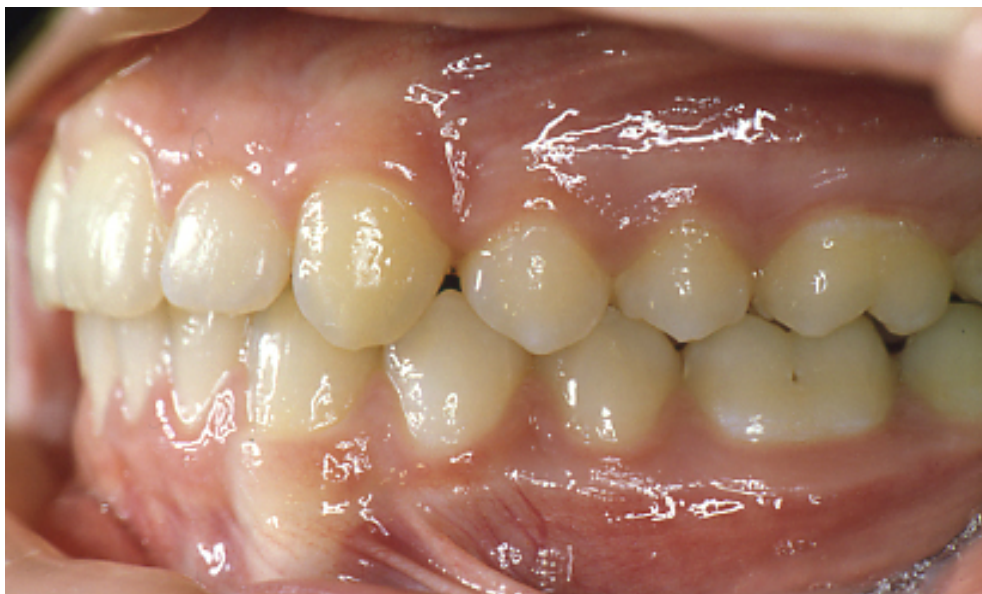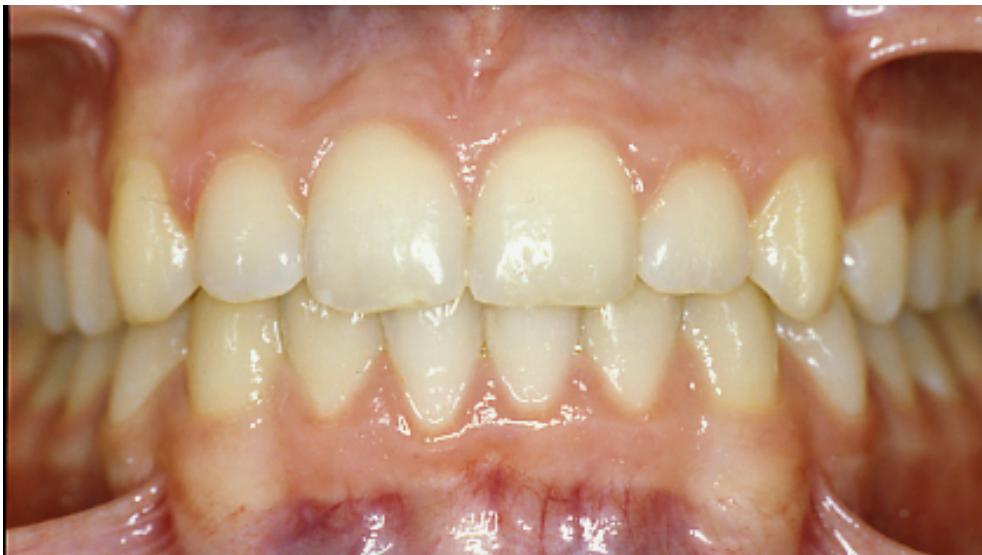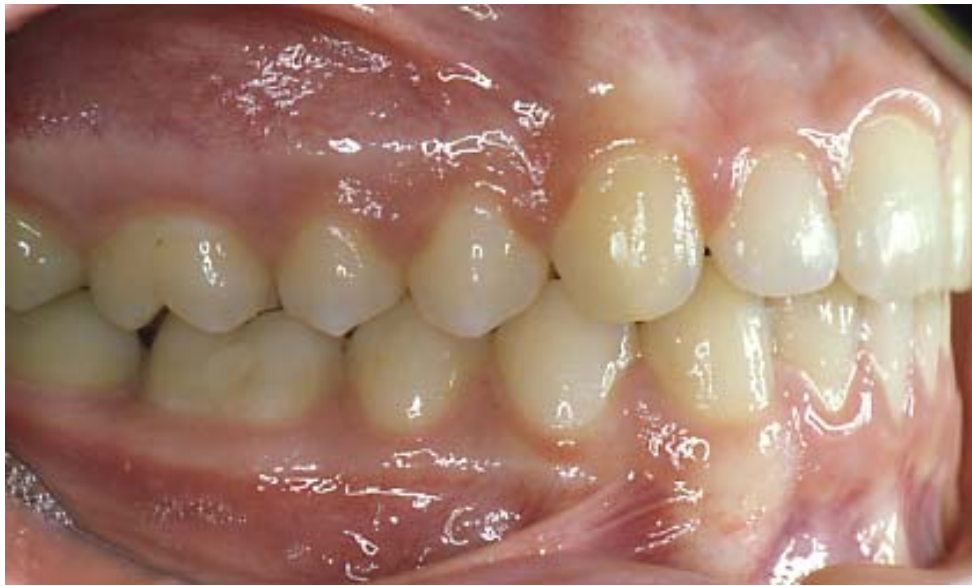Activator – Headgear

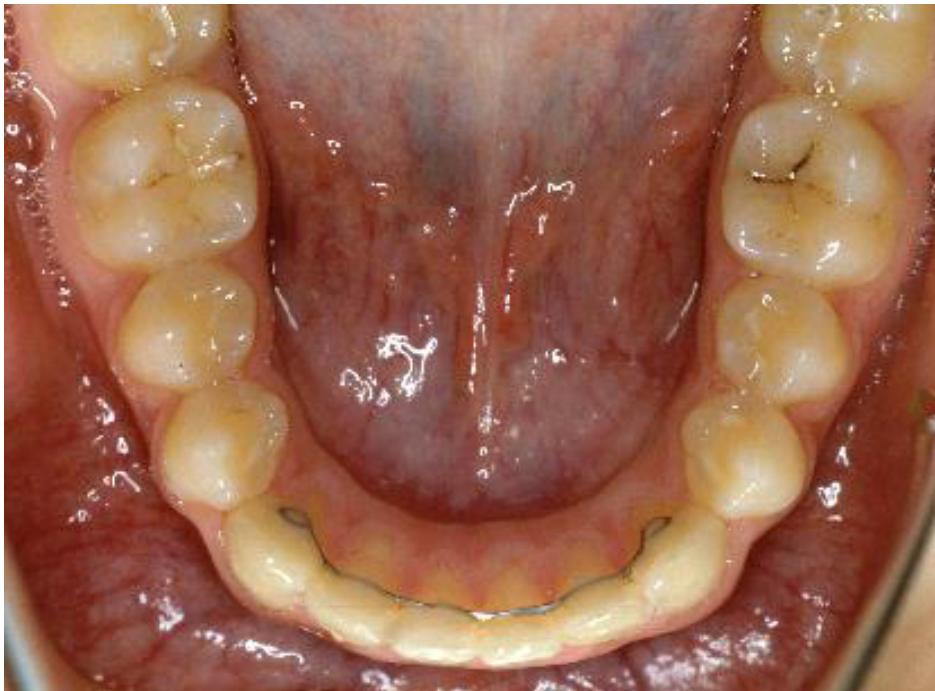
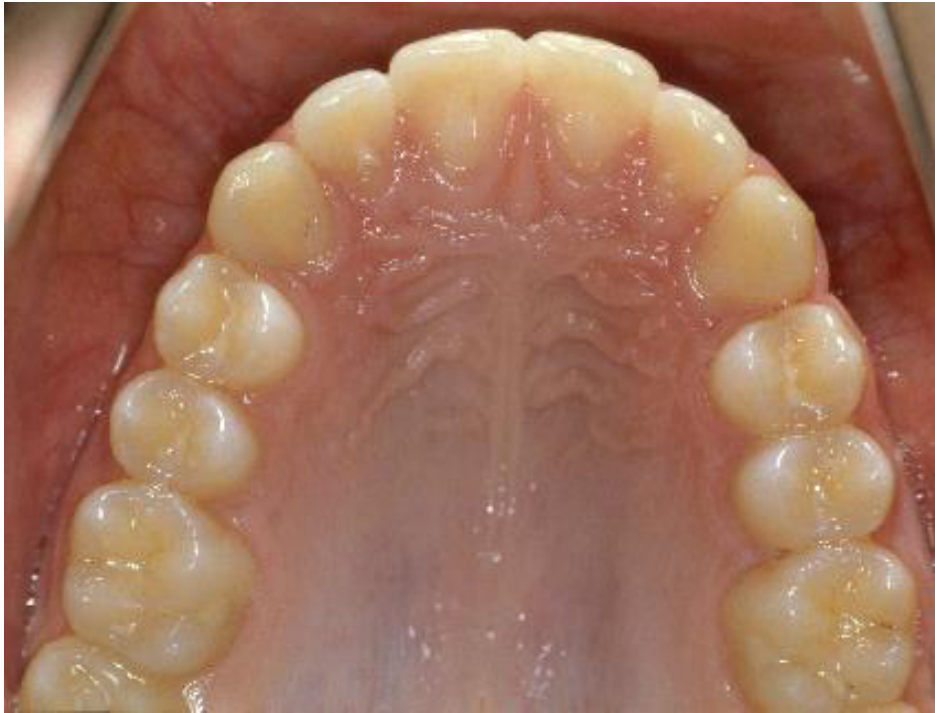

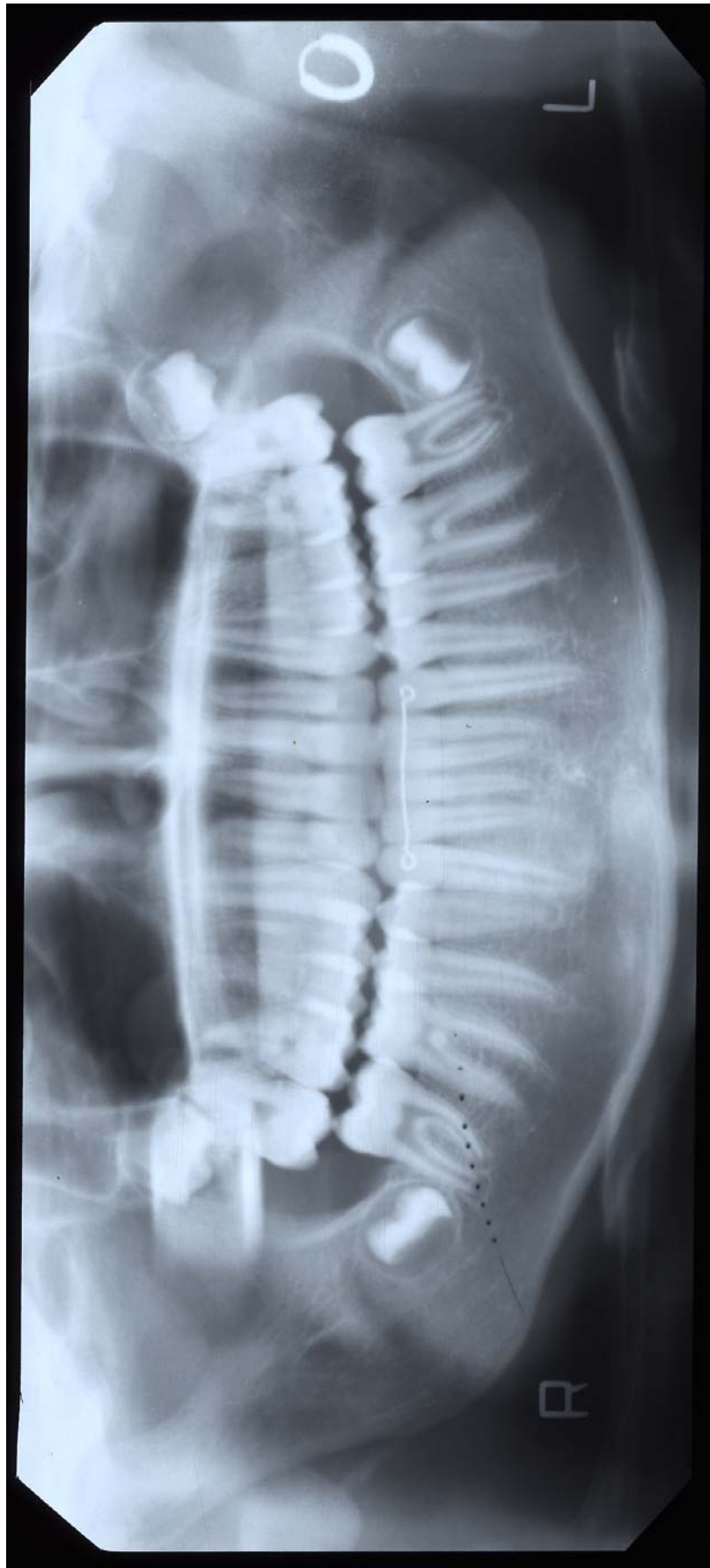Edgewise appliance

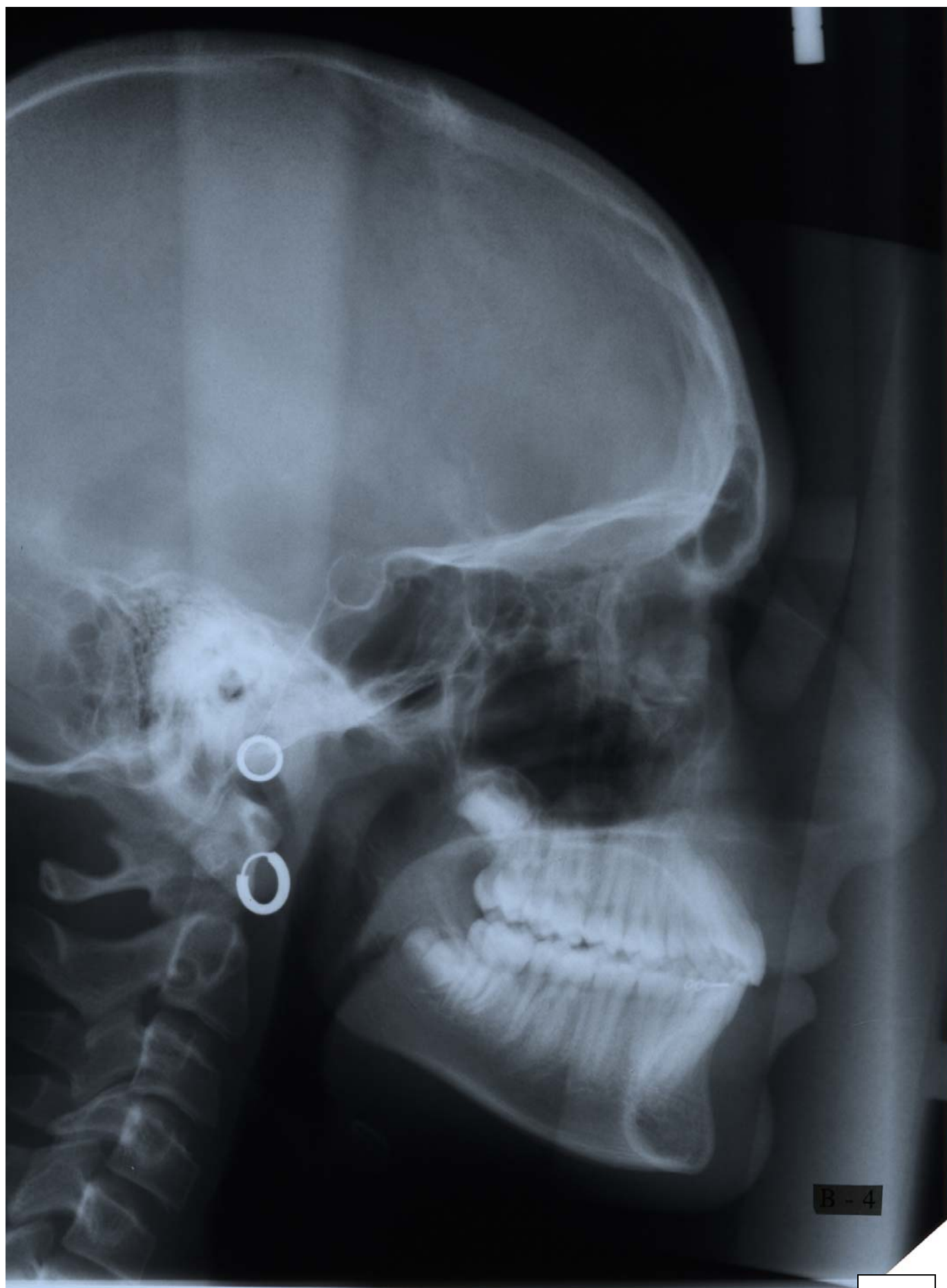

B-1







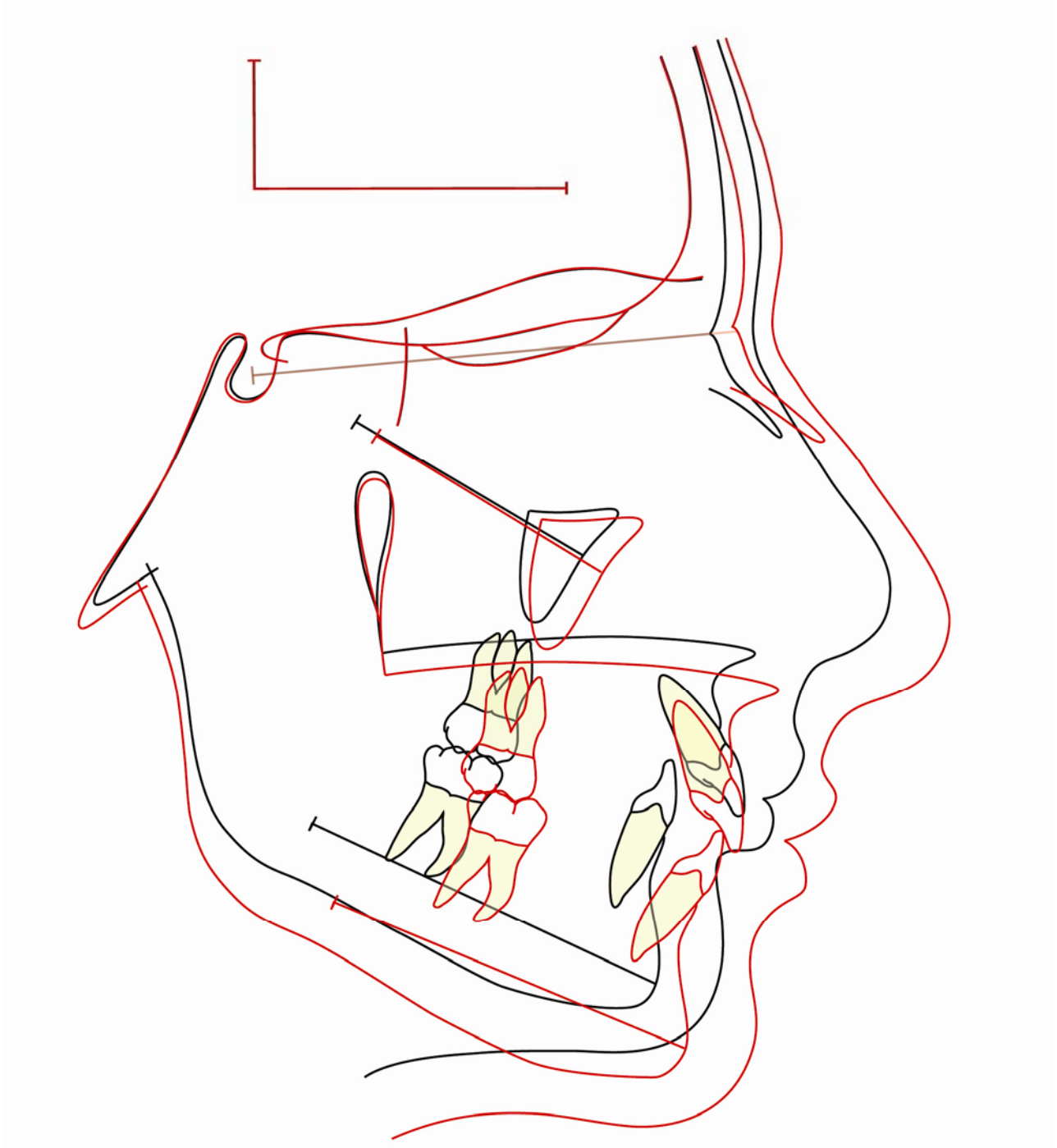


B - 4


B-4

[illegible]

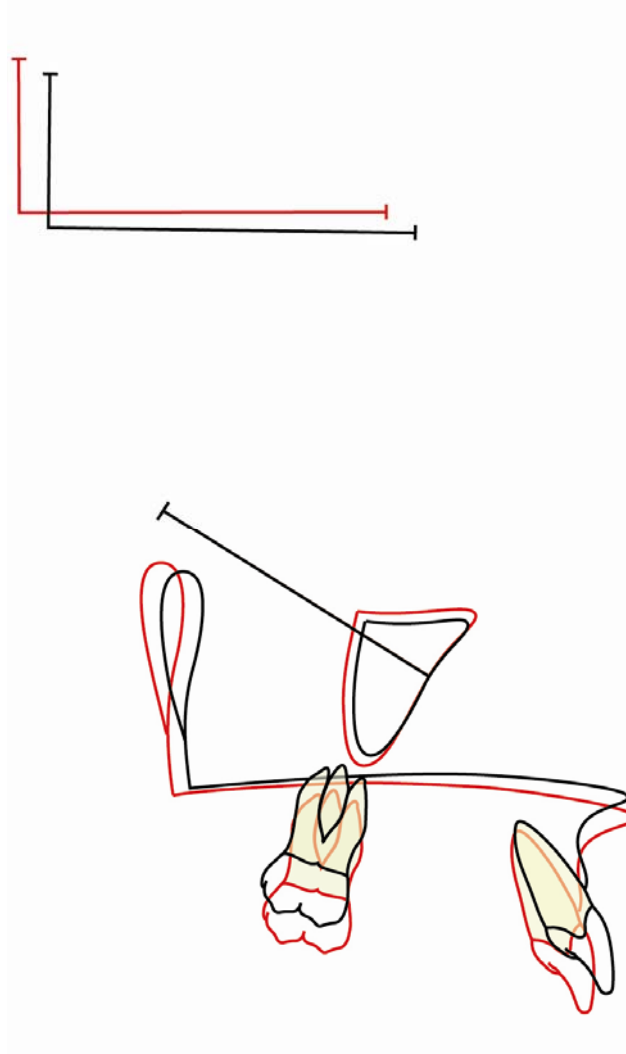
Case J.L.
Pre – Treatment 10⁶
Post – Treatment 13⁴



Case J.L.
Pre – Treatment 10^6
Post – Treatment 13^4



Case J.L.
Pre – Treatment 10^6
Post – Treatment 13^4



CHEPHALOMETRIC MORPHOLOGICAL ASSESSMENT II

Sagittal Skeletal Relations

Maxillary Position
S-N-A
Mandibular Position
S-N-Pg
Sagittal Jaw Relation
A-N-Pg

Pretreatment	Posttreatment	Mean	SD
85°	84°	82°	3.5
80°	81°	80°	3.5
5°	3°	2°	2.5

Vertical Skeletal Relations

Maxillary Inclination
S-N/ANS-PNS
Mandibular Inclination
S-N/GO-Gn
Vertical Jaw Relation
ANS-PNS/Go-Gn

5°	7°	8°	3.0
28°	29°	33°	2.5
23°	22°	25°	6.0

Dento-Basal Relations

Maxillary Incisor Inclination
I - ANS-PNS
Mandibular Incisor Inclination
I - Go-Gn
Mandibular Incisor Compensation
I - A-Pg (mm)

118°	113°	110°	6.0
88°	100°	94°	7.0
-4	2	2	2.0

Dental Relations

Overjet (mm)

Overbite (mm)

Interincisal Angle
I/I

12	2,5	3,5	2.5
7	3,5	2	2.5
129°	126°	132°	6.0

POSTTREATMENT RESULTS

A. Photographs :

Extraoral : The lip closure has normalized, and the face looks harmonious.

Intraoral : The oral hygiene is good and the gingiva is healthy. No decalcification of the enamel took place during the treatment.

B. Dental casts :

Dental stage : DS 4 M 2: (DS 4: All permanent canines and premolars are in occlusion; M 2: All permanent second molars are in occlusion).

The dental casts show a normal class I occlusion on the molars and canines on both sides and the incisal relationship has normalized. There is a slight midline discrepancy, 1mm to the left.

C. Functional analysis :

The lip dysfunction has been corrected, and no muscle or joint problems have developed. No CR-CO discrepancy has developed.

D. Panoramic radiograph :

The panoramic radiograph shows good angulation of the roots. No root resorption can be observed.

E. Cephalometric radiograph :

The class II malocclusion was corrected by a combination of skeletal and dentoalveolar changes. The prognathism of the maxilla was reduced and the prognathism of the mandible was increased by 1°, reducing the sagittal jaw relationship by 2°. The maxillary inclination increased slightly more than the mandibular inclination, leading to a small decrease in the vertical jaw relationship. The upper incisors were slightly retroinclined and the lower incisors were proclined . The mandibular incisors moved forward to a normal position in the face . The overjet and overbite were normalized. The interincisal angle was according to the treatment plan reduced.

F. Growth / treatment analysis :

General facial changes :

During the two year treatment period both jaws grew downward and forward. The mandible grew a little more forward than the maxilla, contributing to the correction of the class II discrepancy. The upper incisors tilted slightly posteriorly and did not move forward in the face, whereas the lower incisors were proclined and moved forward in the face.

Maxillary changes :

The maxillary complex rotated slightly posteriorly in the whole treatment period. The nasal floor rotated posteriorly approximately to the same degree as the maxilla, without the normal remodelling .

The superimposition on the stable structures in the maxilla shows that the upper molars moved forward in the maxilla, and the incisors moved slightly backwards.

The upper arch was expanded during treatment more over the premolars and canines than over the first molars.

Mandibular changes :

The mandible rotated approximately two degrees forward during the observation period, which is slightly less than could be expected in this growth type. This may be due to some bite opening effect of the expansion plate and the fixed appliance. There was good condylar growth in the period, approximately 4 mm per year.

The whole lower arch moved forward on the mandibular base. The incisors tilted 15° and moved 4 mm forward. The molars tilted slightly and moved 3 mm forward , contributing to the class II correction. There was transverse expansion of the lower arch mainly in the premolar area and slight expansion over the lower cuspids.

There was good upward and forward eruption of the mandibular molars of approximately 5 mm, whereas there was practically no eruption of the incisors. This was one of the elements in the correction of the skeletal deep bite.

A. Posttreatment evaluation :

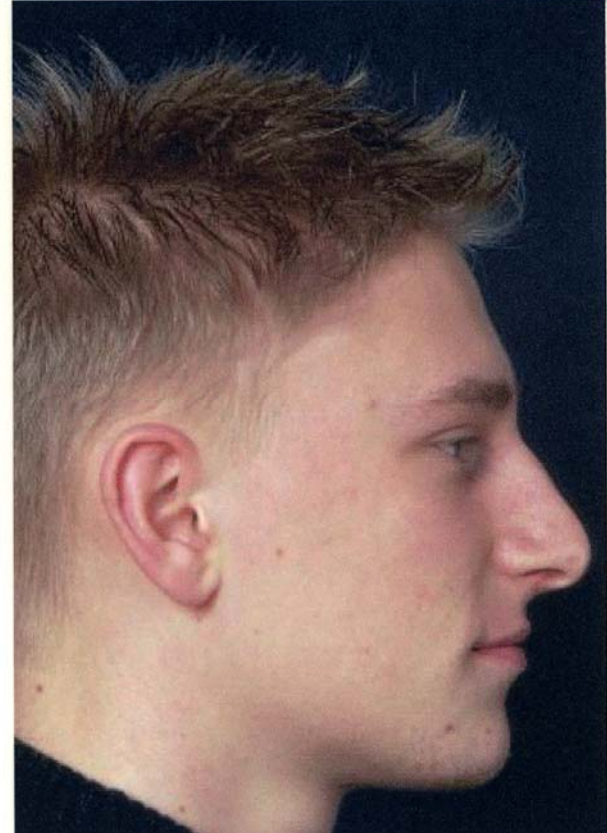
The treatment results were satisfactory. The skeletal and dental class II discrepancy and the skeletal deep bite was corrected to a class I relation with an ideal incisal relationship. The teeth settled in a good, slightly overcorrected class I occlusion, and apart for a minor midline discrepancy (lower midline 1mm to the left) the occlusion was pretty ideal. The facial profile improved considerably. The gingiva was healthy, and no cavities or decalcification appeared during the treatment.

The function was normal. No muscle or TMJ problems developed during treatment. The CR and CO was practically identical.

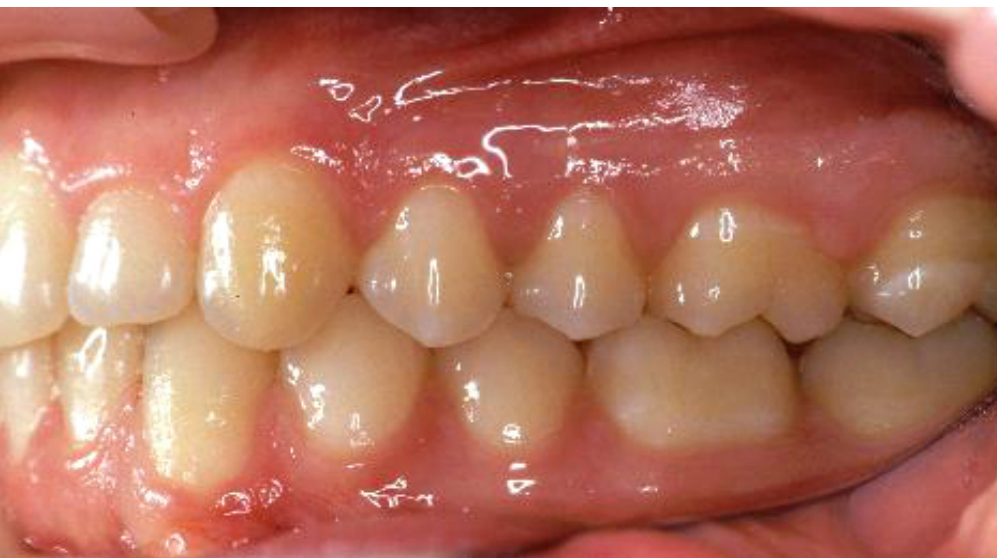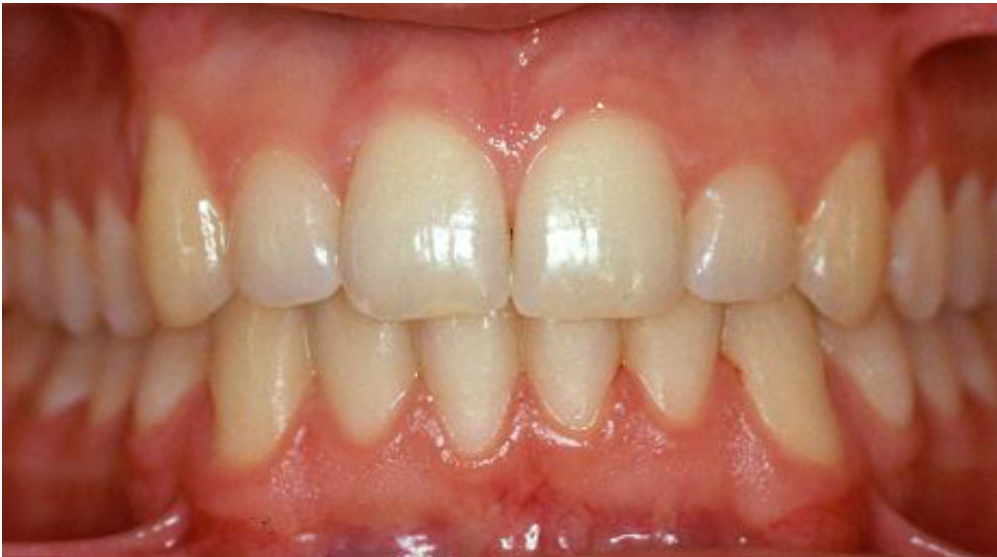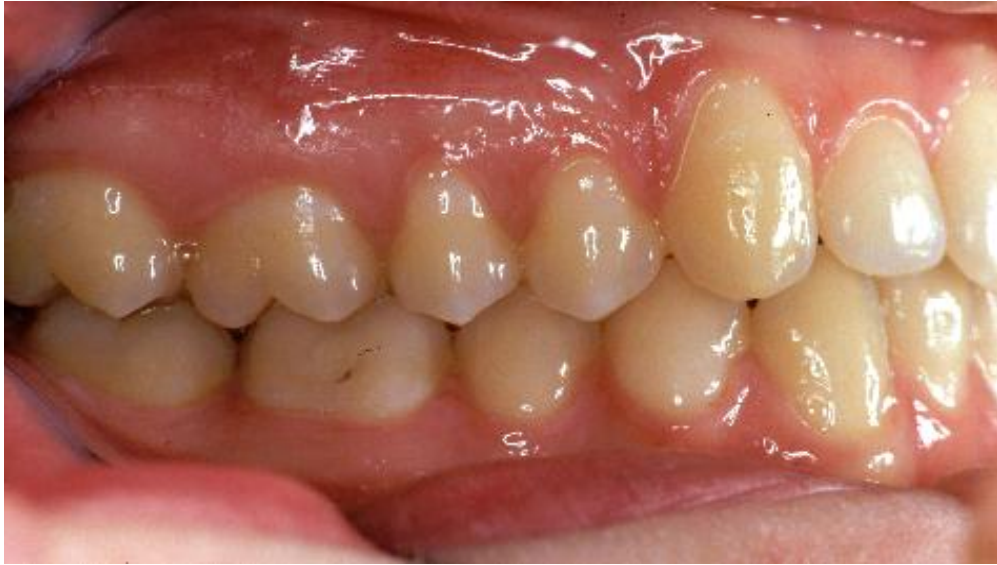B. Retention :

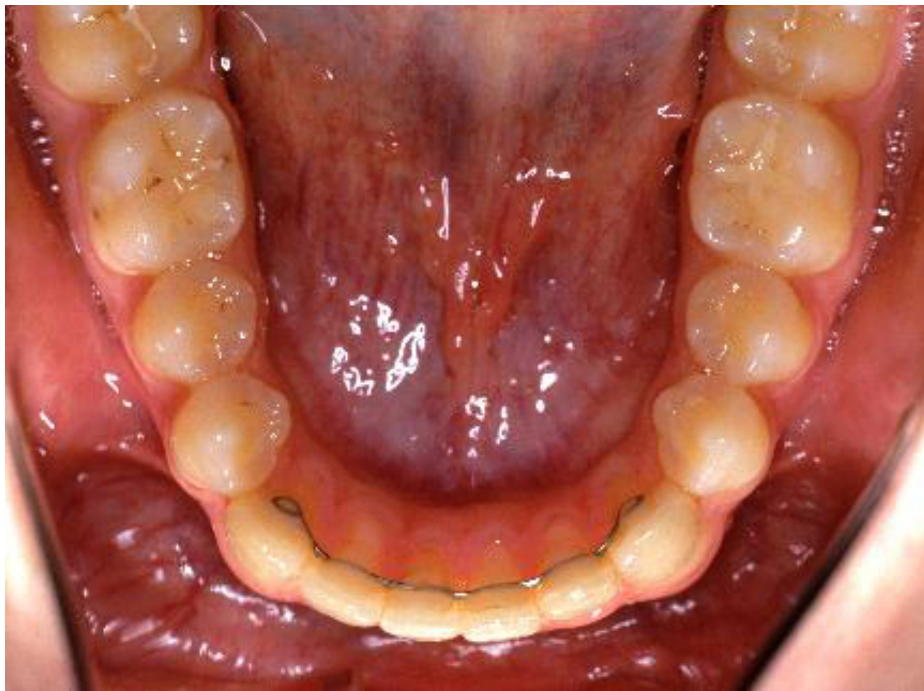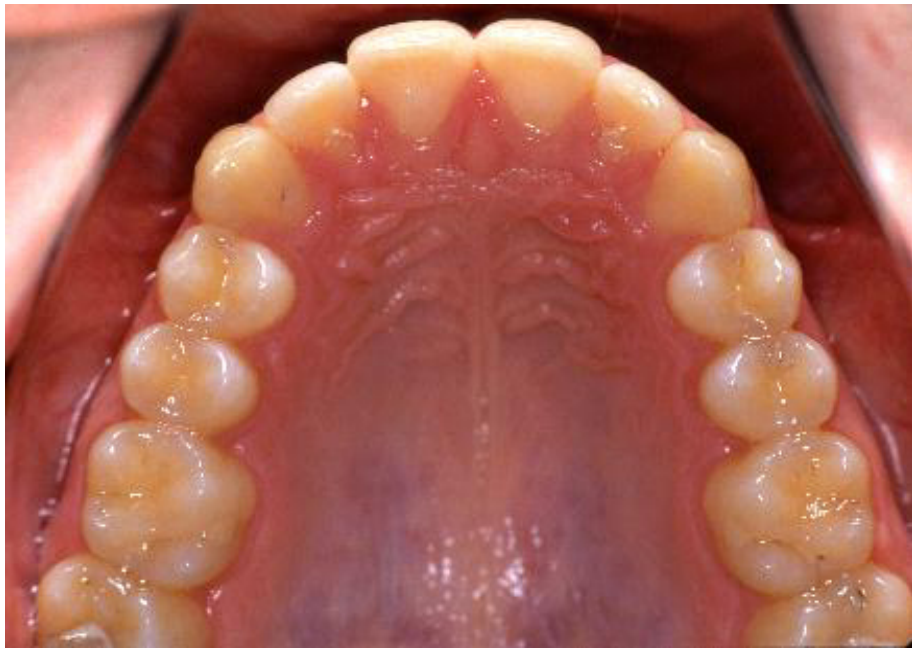The main objectives of the retention phase were to avoid relapse of the deep bite and prevent late crowding of the lower incisors. Therefore a Mini-Activator was chosen together with a 3-3 bonded retainer.

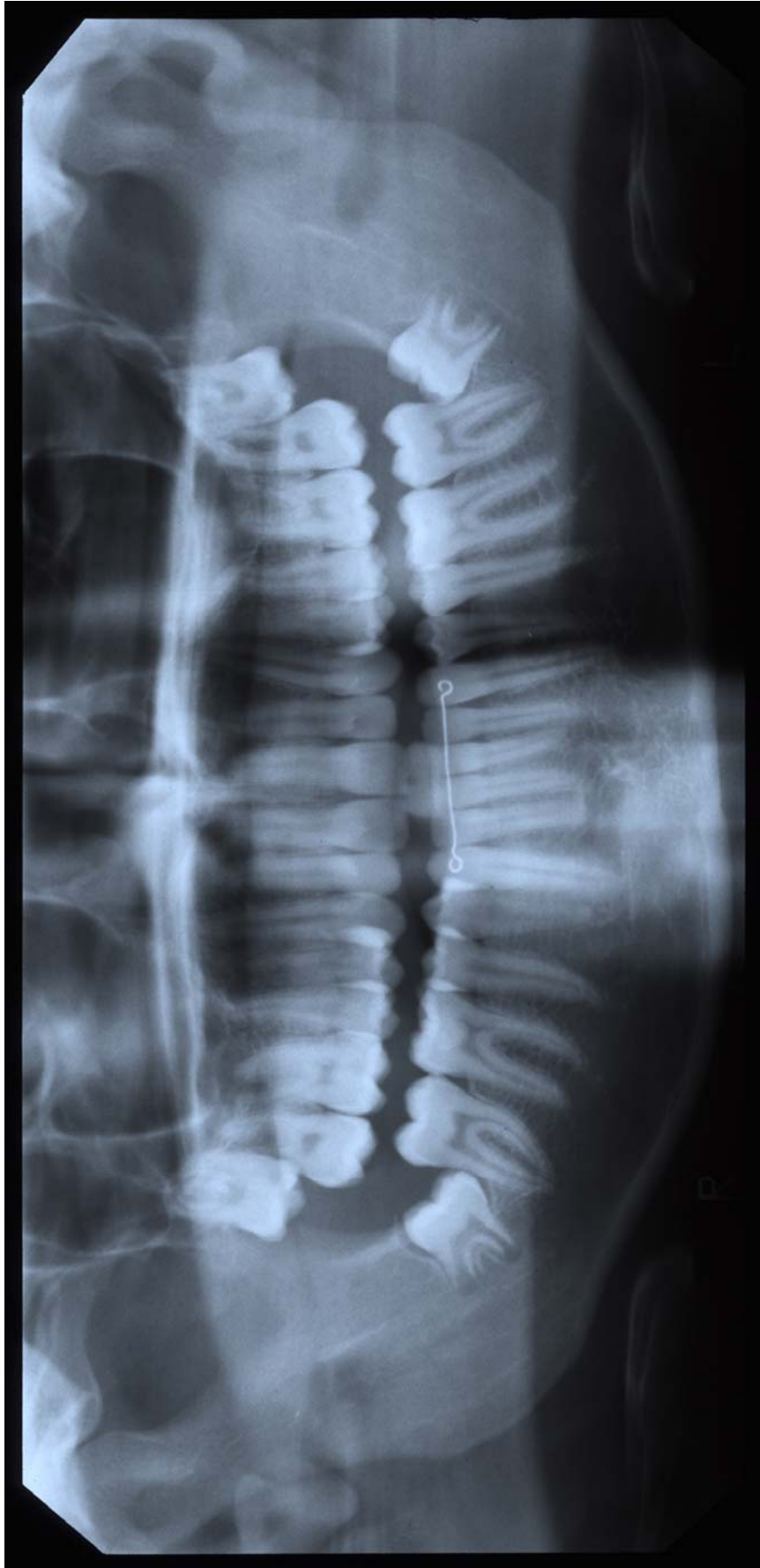The Activator should be used at night for two years and the bonded retainer should remain for many years.



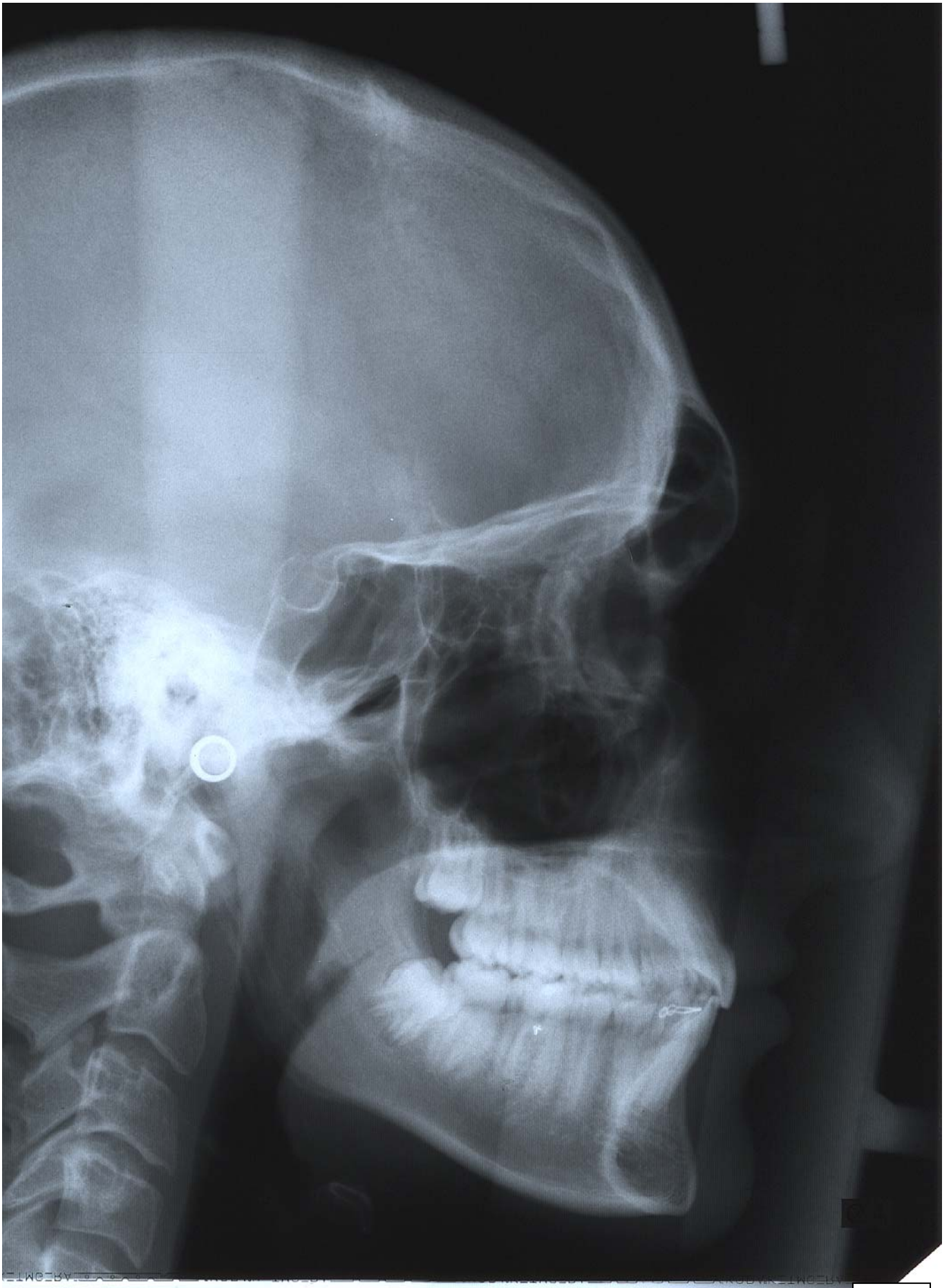C-1







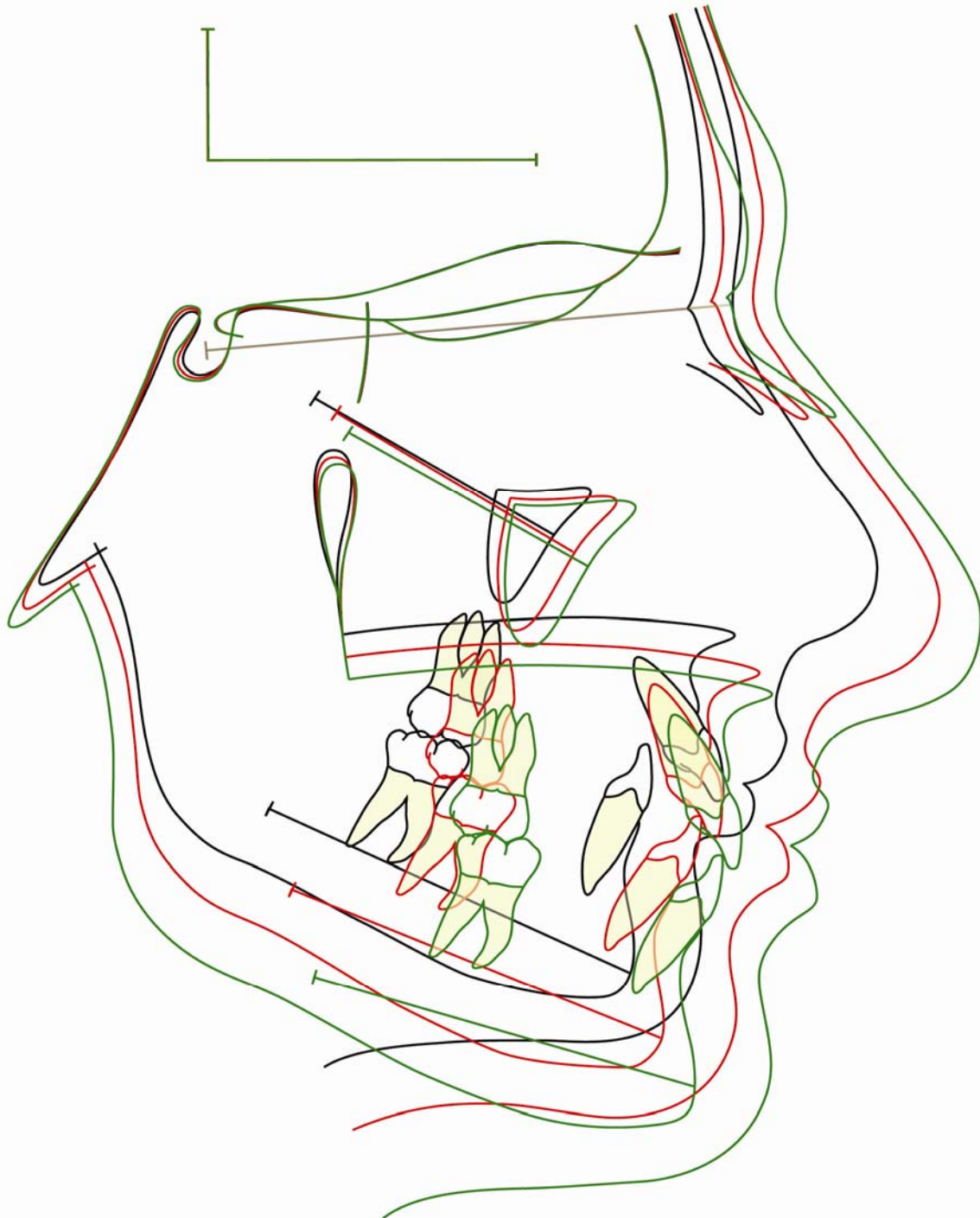
C-3*



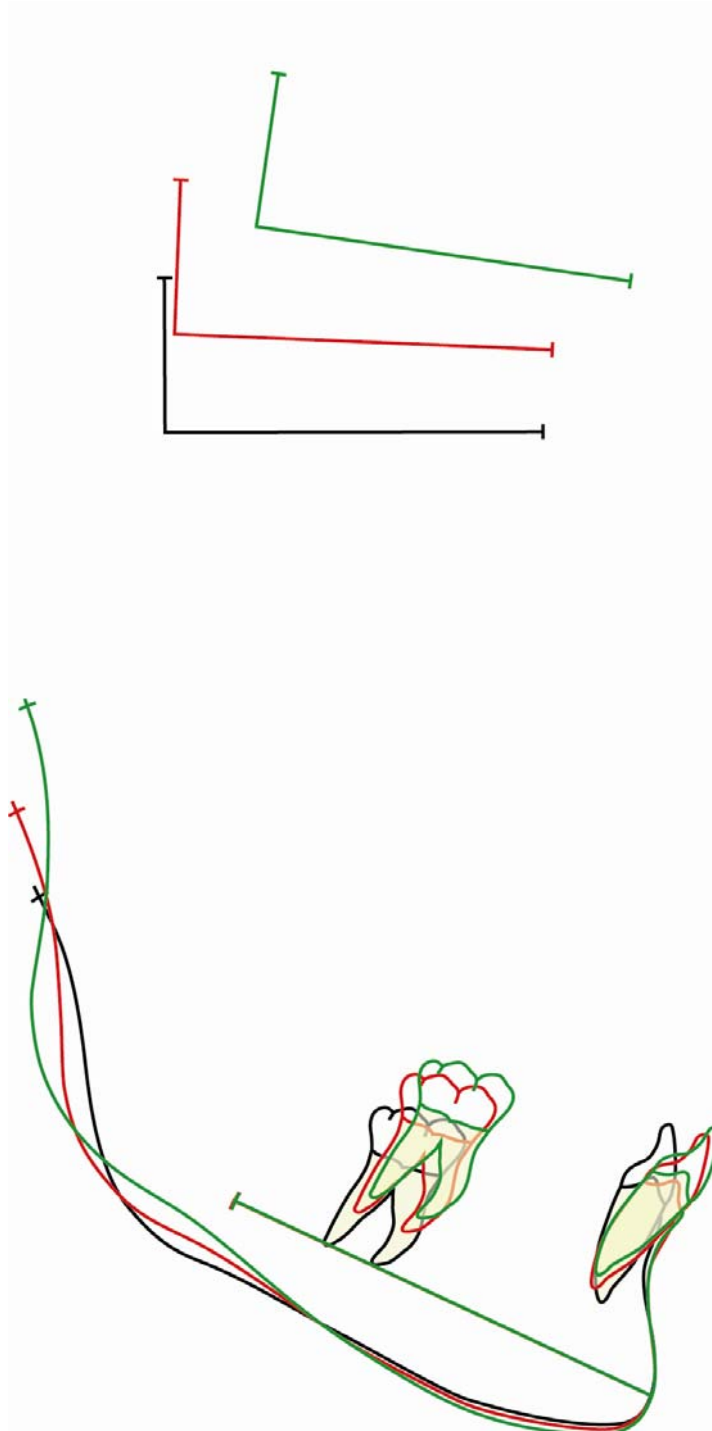
C-4*

[illegible]

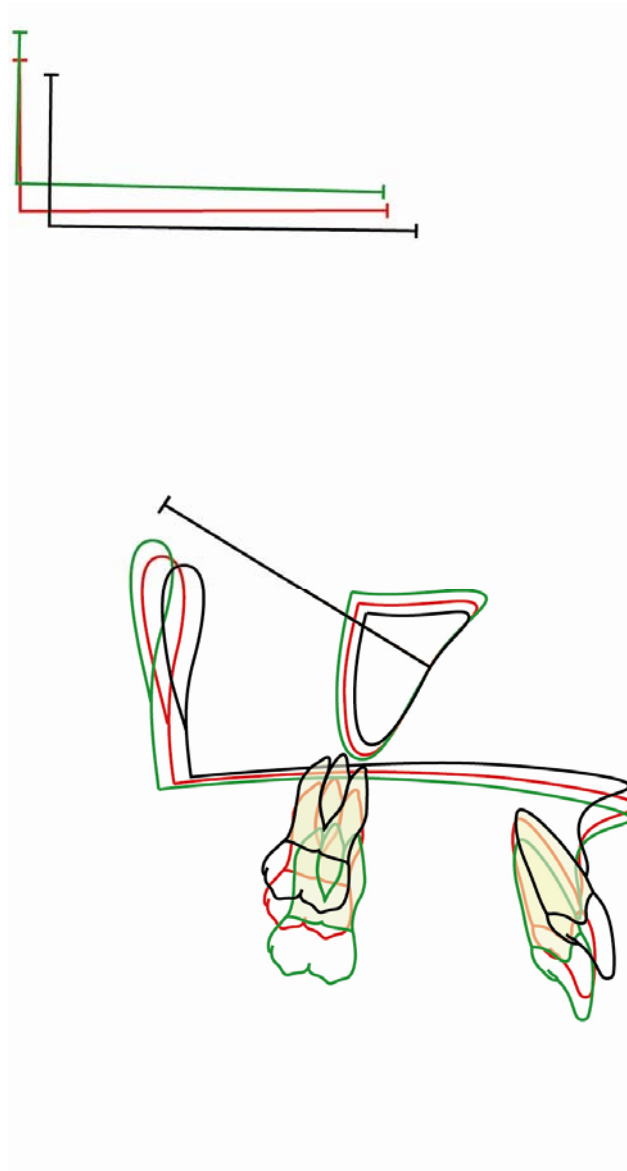
Case J.L.
Pre – Treatment 10⁶
Post – Treatment 13⁴
Post – Retention 17⁹



Case J.L.
Pre – Treatment 10⁶
Post – Treatment 13⁴
Post – Retention 17⁹



Case J.L.
Pre – Treatment 10⁶
Post – Treatment 13⁴
Post – Retention 17⁹



CHEPHALOMETRIC MORPHOLOGICAL ASSESSMENT III

Sagittal Skeletal Relations

Maxillary Position
S-N-A
Mandibular Position
S-N-Pg
Sagittal Jaw Relation
A-N-Pg

Pretreatment	Posttreatment	Out of Retention	Mean	SD
85°	84°	84°	82°	3.5
80°	81°	82°	80°	3.5
5°	3°	2°	2°	2.5

Vertical Skeletal Relations

Maxillary Inclination
S-N/ANS-PNS
Mandibular Inclination
S-N/GO-Gn
Vertical Jaw Relation
ANS-PNS/Go-Gn

5°	7°	7°	8°	3.0
28°	29°	25°	33°	2.5
23°	22°	18°	25°	6.0

Dento-Basal Relations

Maxillary Incisor Inclination
I - ANS-PNS
Mandibular Incisor Inclination
I - Go-Gn
Mandibular Incisor Compensation
I - A-Pg (mm)

118°	113°	112°	110°	6.0
88°	100°	101°	94°	7.0
-4	2	2	2	2.0

Dental Relations

Overjet (mm)

Overbite (mm)

Interincisal Angle
I/I

12	2,5	2	3,5	2.5
7	3,5	2	2	2.5
129°	126°	127°	132°	6.0

POSTRETENTION FINDINGS

A. Photographs :

Extraoral : Good facial harmony with a normal prognathism of the chin and normal lip closure. The nose is relatively big and deviates slightly to the left. The smile line looks ideal.

Intraoral : The oral hygiene is good and the gingiva is healthy. No decalcification or cavities have developed during the treatment or retention. Some gingival recessions are seen on the upper right canine and on the lower canines.

B. Dental casts :

There is a good dental alignment and the occlusion shows a good class I relationship on canines and molars, and the overjet and overbite is ideal. There is a slight midline discrepancy (1 mm, to the left) .

C. Functional analysis :

No TMJ or muscle problems developed during the retention period. The opening movement is symmetrical and of normal magnitude. CO and CR is identical . The lip function is normal.

D. Panoramic radiograph :

The inclination of the roots looks normal. The lower third molars are erupting in a mesial direction, and there is a slight danger that the eruption of the teeth may be impaired.

E. Cephalometric radiograph :

The maxillary prognathism remains stable in the retention period and the mandibular prognathism increases slightly, resulting in a normalization of the sagittal jaw relationship.

The inclination of the maxilla remains stable but the inclination of the mandible decreases considerably leading to a decrease in the vertical jaw relationship by 4°.

The inclination of the upper and lower incisors are practically unchanged. The lower incisors remain in a ideal position in the face.

The overjet and overbite ends up within normal values, and the interincisal angle is slightly decreased.

Hand - wrist radiograph :

The hand - wrist radiograph shows that the epiphysial discs of Radius and Ulna are closed and therefore no more growth in body height can be expected. A small amount of condylar growth can be expected within the next year .

F. Growth / treatment analysis :

General facial changes :

In the retention and postretention period the facial growth continued in a forward-downward direction, with a slightly larger forward component for the mandible. The upper and lower incisors moved forward in the face with pretty much the same angulation. Together with the marked growth of the nose, the profile became less convex.

Maxillary changes :

The maxilla rotated approximately 2° forward in the retention and post-retention period, equalizing the posterior rotation in the treatment period. Both the molars and the incisors retained their antero-posterior position in the maxilla. There was a considerable eruption of the molars (7 mm) and a much lesser eruption of the incisors (2 mm) resulting in a significant anterior rotation of the upper occlusal plane. No changes took place in the transverse dimension of the upper arch.

Mandibular changes :

The condylar growth increased 11,5 mm in the retention and postretention period, with an average growth rate of 2.7 mm per year, a little less than in the treatment period, which was 4 mm per year. The mandible rotated 5° anteriorly in the retention and postretention period, double that in the treatment period. The lower molars moved slightly more forward than the incisors in relation to the stable structures in the mandible. Both the molars and the incisors erupted about 1,5 mm during this period. The lower occlusal plane therefore had the same anterior rotation as the mandible .

POSTRETENTION EVALUATION

The postretention results are pretty close to the posttreatment results. The facial appearance looks nice, and the dental alignment is good and the occlusion remains stable. No abnormal occlusal wear of the teeth took place in the whole observation period. The oral hygiene is perfect and the gingiva is healthy, but there are some gingival recessions on the upper right canine and on the lower canines due to too heavy tooth brushing. No caries or root resorptions developed in the treatment and retention period.

PROGNOSIS

The patient is now 17 years and 9 months, and the growth in body height has ceased. In a boy with this type of anterior growth rotation one would expect at least one more year with a slight amount of condylar growth. This late condylar growth is normally one of the reasons for a late crowding in the lower incisal area, and may also contribute to a deepening of the bite.

With the stability of the occlusion seen more than 3 years after active retention, in a period of considerable growth, it is unlikely to expect a change in the occlusion and a deepening of the bite in the future.

The 3-3 retainer will protect the lower incisors from crowding, and the patient is advised to keep the retainer for many years.

Although the lower third molars are erupting in a mesial direction, there may be a chance for sufficient space. I will therefore observe the eruption of these teeth and perhaps recommend uprighting later.

The patient has no abrasion and functional problems. The oral hygiene is perfect and the occlusion is stable. The patient is advised to avoid too heavy brushing and to use a soft toothbrush to prevent further gingival recessions. The prognosis for the whole dentition seems very good.